



2025

KARNATAKA RADIOLOGY EDUCATION PROGRAM

PATIENT DATA

Name: Mr.X

Age/sex: 50 –year-old male

Place:hubballi

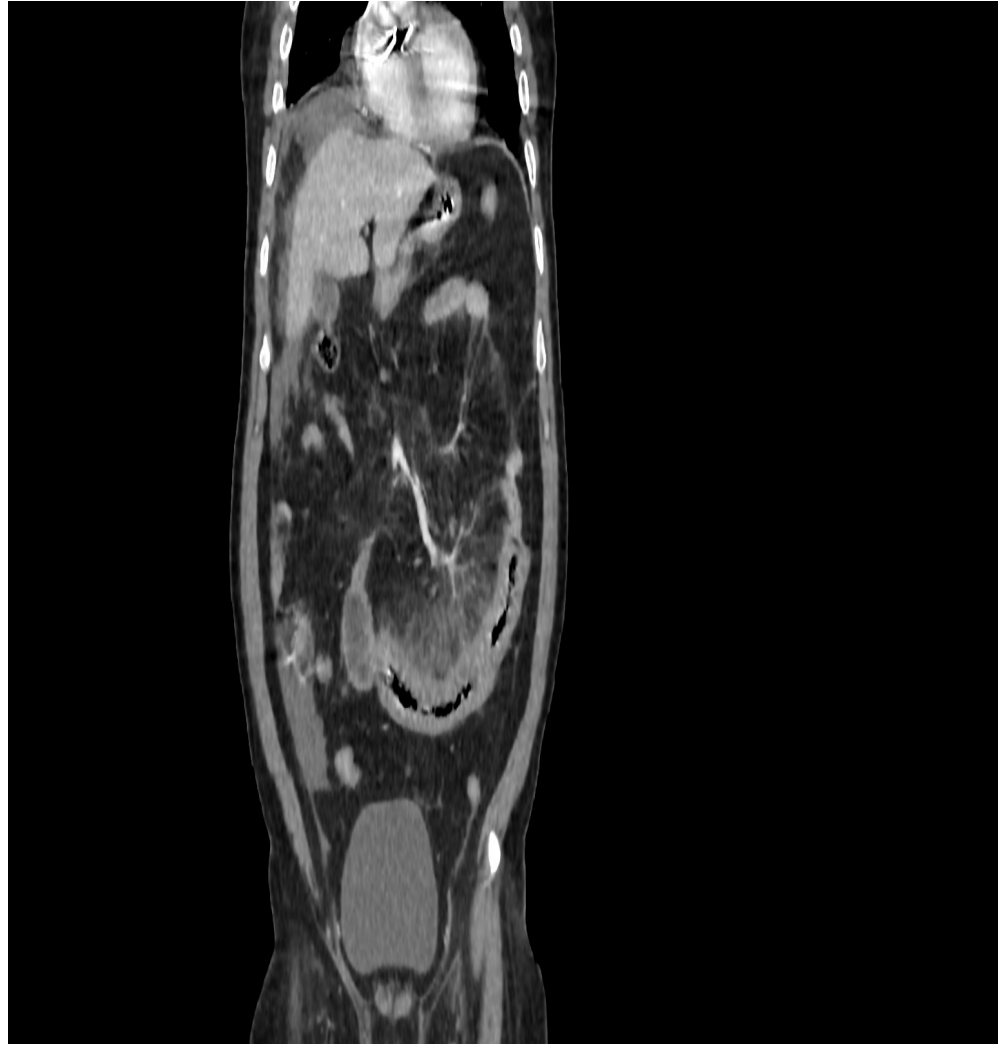
Chief camplaints:

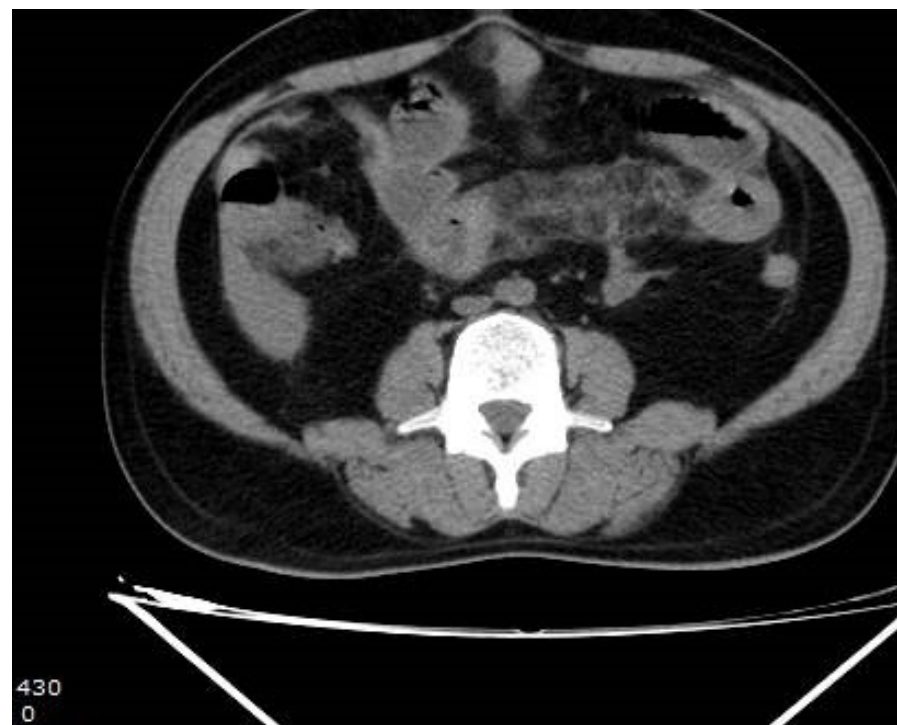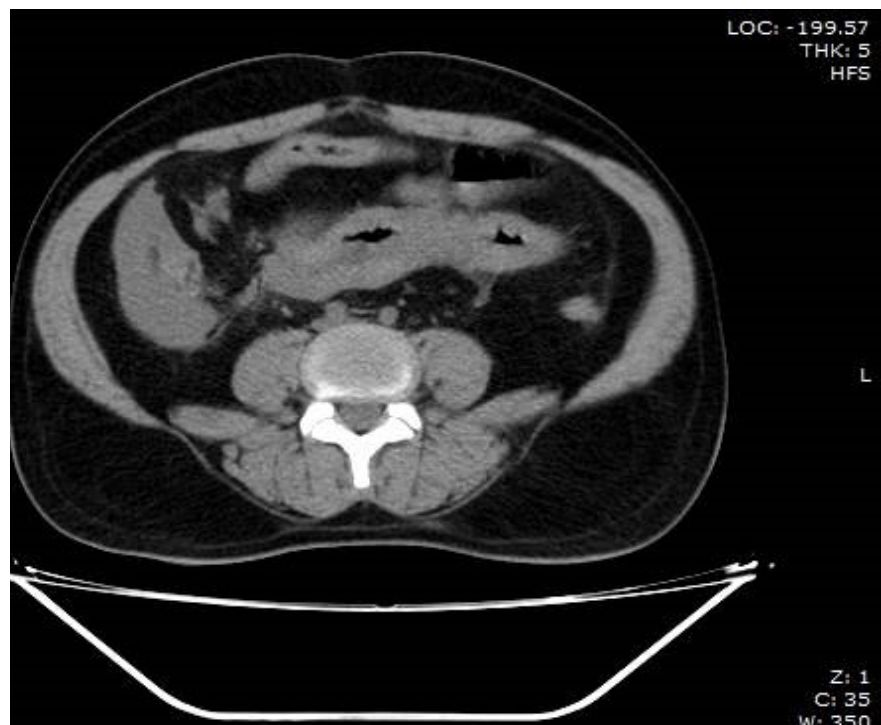
- **Abdominal pain and repeated diarrhea since 1 months**
- **No other comorbidities.**

History of presenting illness:

- **Abdominal pain since 1 months ,dull aching**
- **Diarrhea since 1 months**
- **Also History of wieght loss,and fatigue .**

CECT





CECT FINDINGS

- **CIRCUMFERENTIAL EDEMATOUS AND ENHANCING WALL THICKENING OF SHORT SEGMENT OF DISTAL JEJUNAL LOOP WITH FAT STRANDING THICKENING , MESENTERIC PROLIFERATION AND CONGESTION (POSITIVE COMB SIGN) IN ITS MESENTRY.**
- **IMPRESSION:
FEATURES SUGGESTIVE OF CHRON'S DISEASE WITH COMBS SIGN POSITIVE.**

Mentors

Dr.J.G Suttagatti

HOD AND PROFESSOR

DEPT OF RADIODIAGNOSIS

KMCRI HUBLI

Dr.G C PATIL

PROFESSOR

DEPT OF RADIODIAGNOSIS

KMCRI HUBLI

All Professor and teaching staff,dept of radiodiagnosis

KMCRI HUBLI